

## PATIENT

Paisley Wilson

## SPECIES

Canine

## BREED

Aussie

## SEX

FS

## AGE

7

## WEIGHT

15.5

## INTERPRETED BY

R. McKenzie Daniel,  
DVM, DABVP  
(Canine and Feline)

## IMAGING PERFORMED BY

Jenn

## HOSPITAL NAME

Rockaway Animal  
Hospital

## REFERRING VET

Dr Maniar

## INVOICE 24078

DATE  
03/02/2026

## PRESENTING CLINICAL SIGNS

hematemesis

## ULTRASONOGRAPHIC EXAMINATION OF THE ABDOMEN

### Urinary System

The urinary bladder, trigone, cystourethral junction, and visible pelvic urethra to a depth of 3 cm exhibited normal thickness and tone. Anechoic urine was present in the lumen with no evidence of urine/lumen sediment, mineral, or calculi. The ureteral papillae were normal. The ureters were not visible which is normal. No evidence of inflammatory or neoplastic changes was noted.

Normal size and margination were present in the kidneys. A normal 1:3 cortex / medulla ratio and normal corticomedullary definition were maintained. The echogenicity of the cortex was similar to or slightly less than normal liver parenchyma while the medulla echogenicity was hypoechoic to the cortex with no evidence of pelvic dilation. The left kidney measured 4.0 cm in length. The right kidney measured 4.2 cm in length.

The area of the aortic trifurcation was free of pathology.

### Adrenal Glands

The left adrenal gland was uniform in size and contour with a uniformly hypoechoic parenchyma. The left adrenal gland measured 0.49 cm width at the caudal pole. The right adrenal gland was uniform in size and contour with a uniformly hypoechoic parenchyma. The right adrenal gland measured 0.48 cm width at the caudal pole.

### Spleen

The spleen exhibited a finely textured and homogenous parenchyma which was hyperechoic to the liver and renal cortical parenchyma. The capsule was smooth and regular without apparent expansion. The splenic vasculature at the hilus was normal in volume with no evidence of congestion or thrombosis. Acute to chronic inflammatory, neoplastic, or benign parenchyma changes were not noted.

### Liver/Gallbladder

The liver was subjectively normal in size, structure, and contour. The liver parenchyma was uniform and hypoechoic to the spleen with a mild coarse echotexture. Normal vascular volume. The hepatic and portal vasculature were normal in appearance without signs of congestion. The gallbladder was non-distended in size with thin walls and mild non-organized debris. The cystic and common bile ducts were normal.

### Gastrointestinal

The stomach presented mild thickened wall. Intact wall layering was maintained and distinct. The stomach contained a mild amount of anechoic fluid.

The small intestine presented intact wall layering with 1:3 muscularis/mucosa ratio. The lumen of the small intestine was empty with no signs of mechanical/metabolic ileus, obstruction or foreign material.

Normal visible colon wall layers were present with apparent formed feces in lumen.



**PATIENT**

Paisley Wilson

**Pancreas**

The area of the pancreas was sonographically normal.

**SPECIES**

Canine

**Free Abdomen**

No omental masses, overt lymphadenopathy or peritoneal effusion was present.

**BREED**

Aussie

**ULTRASONOGRAPHIC FINDINGS**

**Primary**

- Mild hypomotile gastritis pattern
- Normal empty small intestine
- Normal area of pancreas
- Mild non-organized gallbladder debris (non-mucocele)

**SEX**

FS

**INTERPRETATION OF THE FINDINGS & FURTHER RECOMMENDATIONS**

**AGE**

7

Empirical therapy for gastritis including broad spectrum gastric protectants and dietary trial should prove beneficial. Sonographic monitoring or reassessment if persistent hematemesis is recommended. No evidence of foreign material or mechanical obstruction. A resting cortisol level to rule out occult Addisons disease is suggested.

**WEIGHT**

15.5

**INTERPRETED BY**

R. McKenzie Daniel,  
DVM, DABVP  
(Canine and Feline)

**IMAGING PERFORMED BY**

Jenn

**HOSPITAL NAME**

Rockaway Animal  
Hospital

**REFERRING VET**

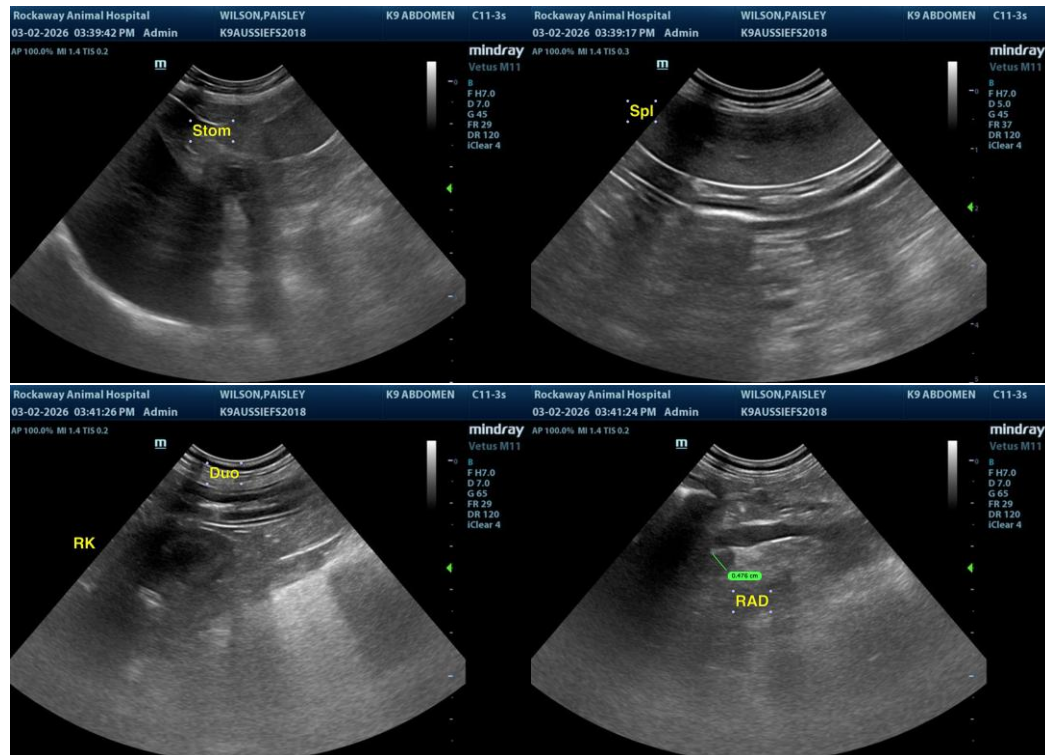
Dr Maniar

**INVOICE**

24078

**DATE**

03/02/2026





**PATIENT**

Paisley Wilson

**SPECIES**

Canine

**BREED**

Aussie

**SEX**

FS

**AGE**

7

**WEIGHT**

15.5

**INTERPRETED BY**

R. McKenzie Daniel,  
DVM, DABVP  
(Canine and Feline)

**IMAGING PERFORMED BY**

Jenn

**HOSPITAL NAME**

Rockaway Animal  
Hospital

**REFERRING VET**

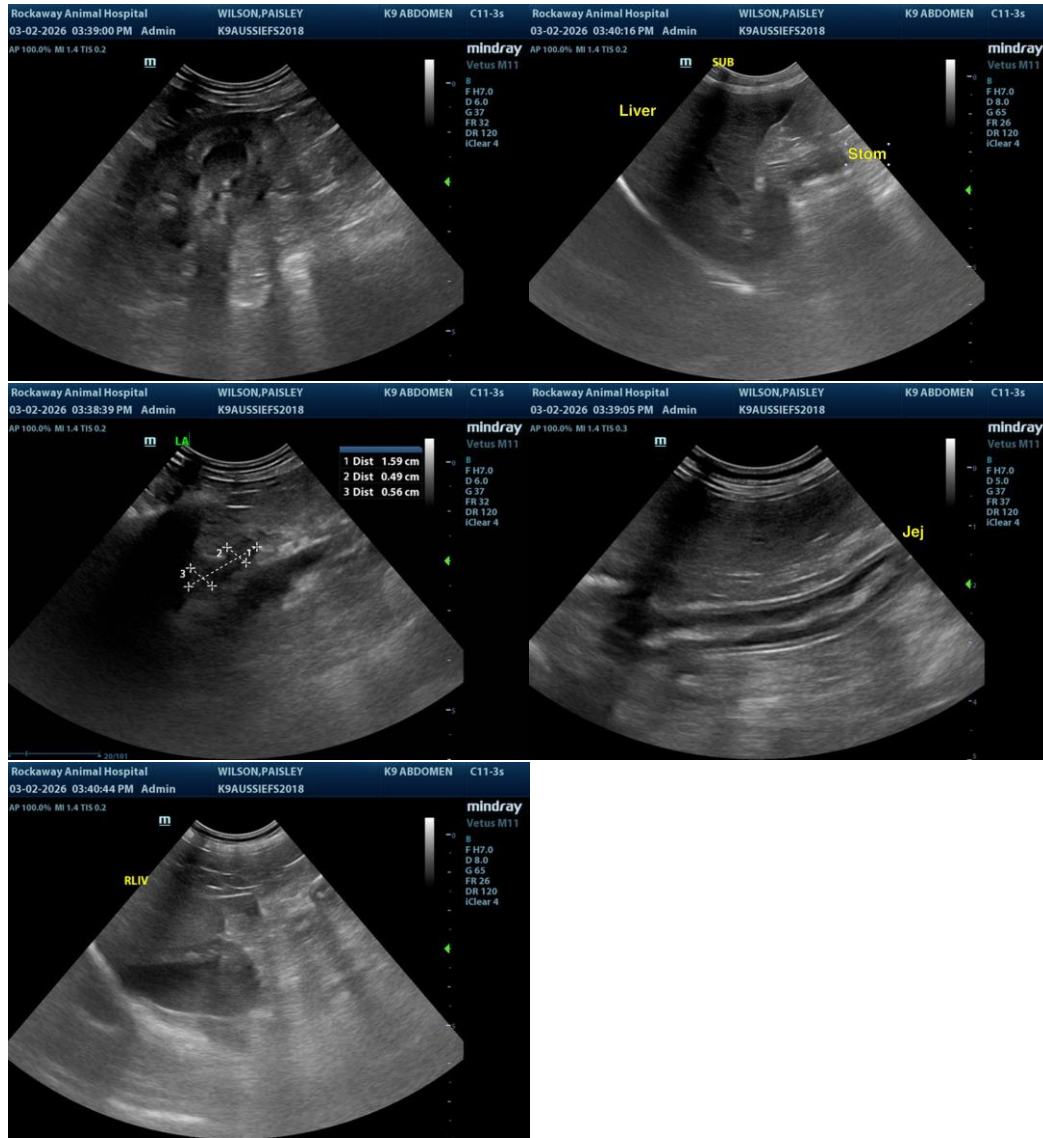
Dr Maniar

**INVOICE**

24078

**DATE**

03/02/2026



The information and recommendations provided are based on the images presented by the referring veterinarian/sonographer. No evaluation can be communicated regarding pathology that was not visible in the image/video clips provided.

Thank you for this referral. If the clinical or image interpretation does not parallel your findings or if I can be of any further assistance, please contact me.

R. McKenzie Daniel, DVM, DABVP (Canine/Feline Practice)  
[info@sonopath.com](mailto:info@sonopath.com)